

VID-10

Upper pole supra costal single puncture PCNL in management of stag horn calculi

M. Elkhoully

Zulekha Hospital, Dubai, United Arab Emirates

In this video we will review the technique of supra costal approach for pcnl adding to formal lower pole many advantages is gained through that technique.

We will first see ct scans of some of the difficult stag horn and there assessment spiral in space application of the CT scan.

Preop assessment and how decision is taken.

Retrograde catheter fixation.

Prone position and puncture of the kidney with c arm control with the amplatz dilatation and sheath fixation.

Identification of stone morphology and comparing with the CT view orientation.

Lithoclasting and technique of extraction of the branches from each calyx.

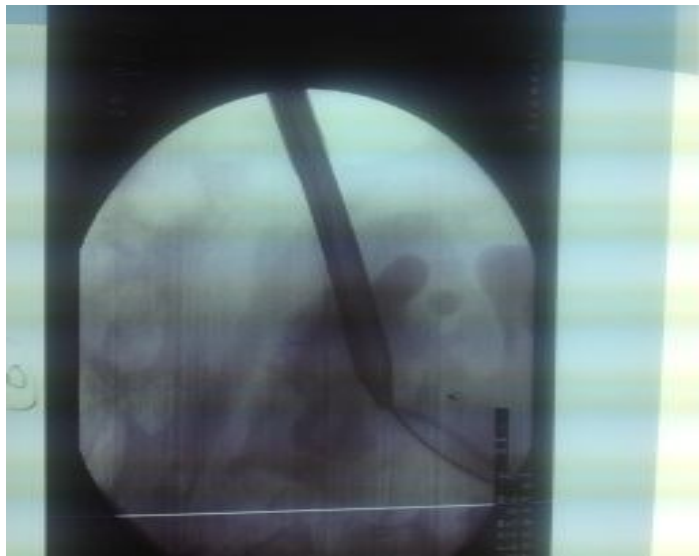
Flexible renoscopy and laser fragmentation.

Dj stenting .

Post operative view and control ct for assessment of residual.

Overall assessment of the technique.

Figure 1. Uppertext



As published in the *Supplement of AFJU, Volume 18 (2012), 1st ESD "Experts in Stone Disease" Conference (page8)*